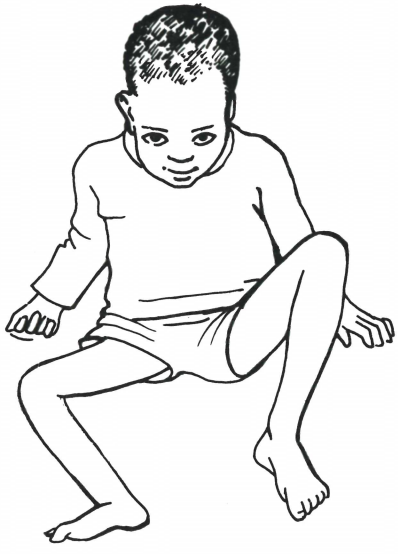
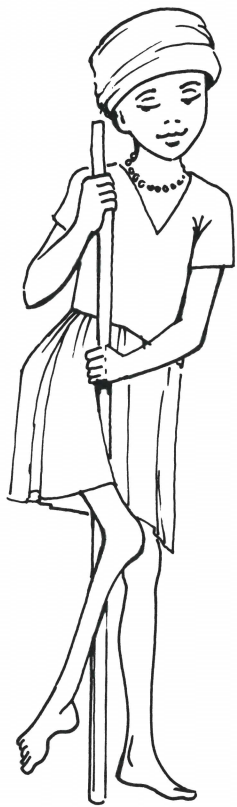
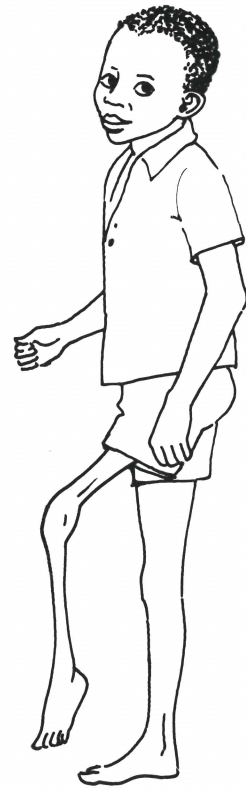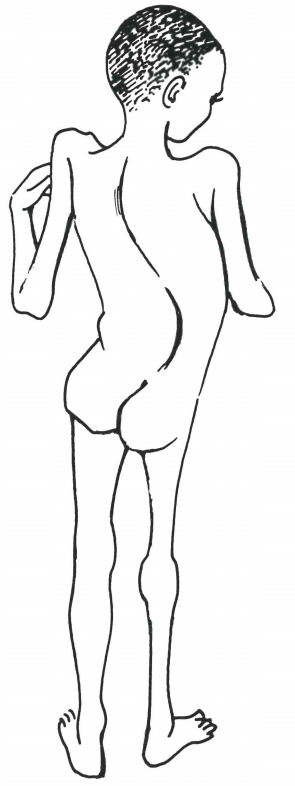Flexion contracture knees and left hip. Abduction contracture right hip.



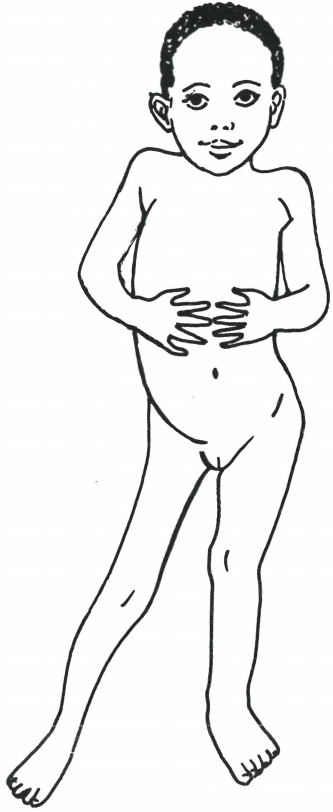
External rotation and flexion deformity right hip with calcaneocavus right foot due to calf paralysis.



Flexion deformity of left hip in flail leg.



Paralytic scoliosis with paralytic shortening of right leg.

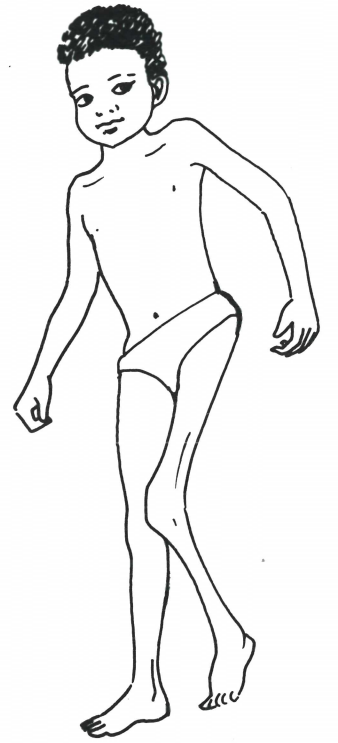


Abductor contracture right hip

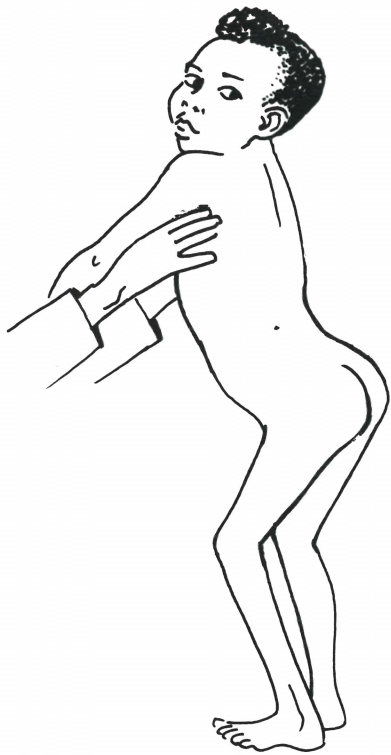
Your disabled child?

These are some of the less severe polio disabilities. A child or young person with a disability similar to one shown on this page has probably been disabled by polio. He or she should be taken to a health centre or hospital to find out what treatment or exercises can help. Advice can also be sought on equipment which is available or can be made at home to assist a disabled person. The sooner a child is taken for expert advice - once the initial fever is over - the greater the chances are that some movement will come back to the paralysed limbs.

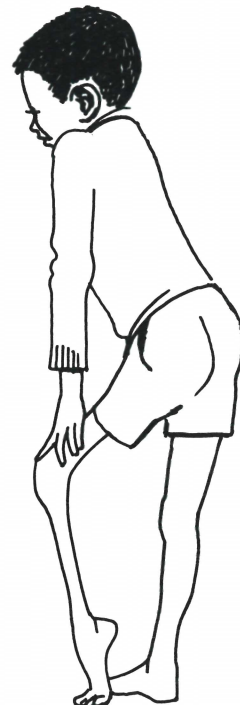
The medical description of each disability is included.



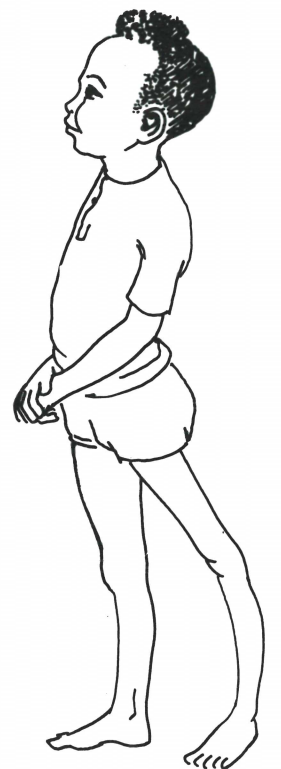Paralytic dislocation of left hip.



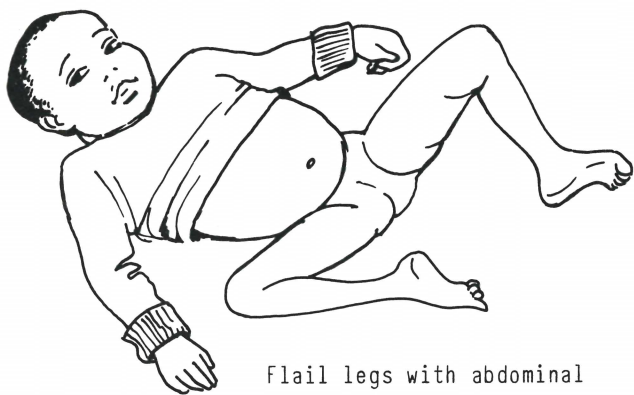
Back and hip extensor muscle paralysis.



Left quadriceps paralysis. Equinus foot and flail leg.



Hamstring paralysis left leg with genu recurvatum (back knee).



Flail legs with abdominal muscle weakness